

Tetralogy of Fallot with Brain Abscess

RAMACHANDRAN MUTHIAH

MORNING STAR HOSPITAL, MARTHANDAM, KANYAKUMARI DISTRICT, INDIA

Cyanotic heart disease accounts for 12.8-69.4 % of all cases of brain abscess with the incidence being higher in children and TOF (Tetralogy of Fallot) is the most common association in 13-70 % of cases. The intracardiac right-to-left shunting of unsaturated blood increases the risk of paradoxical embolism and seeding of infective pathogens in the shunted blood from the right side of the heart causes infection of brain parenchyma, resulting abscess formation. Structural changes in the heart that create turbulence and shear force in blood flow damage the endocardium, exposing the subendocardial collagen and extracellular matrix. Pathogenic organisms may settle in and infect the endocardium and limited blood supply to the damaged area leads to the formation of vegetation. These friable vegetations may embolize and escape the pulmonary phagocytic clearance of pathogens. The ischemic injury from hypoxaemia and polycythaemia, resulting low perfusion areas (microinfarcts) in the brain which may act as a nidus for infection. Headache, vomiting episodes and stiff neck may herald the onset of brain abscess. The inoculation of an organism occurs hematogenously from the infected vegetations and a single organism is isolated in majority of bacterial brain abscess. *Bacteroides fragilis* and *peptostreptococcus* are the most common anaerobic organisms isolated in cyanotic brain abscess. Echocardiography plays a key role in the diagnosis of infective endocarditis (IE) in TOF. Vegetation can occur on pulmonary and tricuspid valves and large vegetation may attach to the crest of interventricular septum.

Brain abscess is an encapsulated inflammation, fever subsides when encapsulation occurs and can be easily diagnosed by CT scan. The neuroimaging features of brain abscess vary with lesion stage and during the cerebritis stage (local suppurative encephalitis or immature abscess), ring enhancement may be absent or incomplete. The uniformly enhancing capsule is typical of mature abscess. The abscess gradually shrink, peripheral edema diminishes and then disappears in the late capsule stage. In about 50% of cases, the medial wall of an abscess is thinner than the lateral one and is thought to be due to the relatively poor vascular supply of the white matter. This explains the tendency of abscess to rupture into the ventricles and the development of secondary abscesses (daughter abscess) medially, may be seen near the primary lesion. The intraventricular rupture of brain abscess (IVOBRA) results in severe headache, an increase of meningeal irritation, a rapidly deteriorating clinical condition, and an enhancement of the ventricular wall adjacent to the abscess. The brain abscess may spontaneously bleed, presenting as an intracerebral hemorrhage. MRI is more sensitive to distinguish cerebritis from necrosis and the diffusion-weighted imaging can aid to differentiate abscess from the neoplasm. MRS (Magnetic resonance spectroscopy) appears to be useful in the diagnosis of abscesses arising from anaerobic infections because these species produce lactate and acetate, which are readily apparent on MRS and rarely found within tumor tissue.

The treatment of brain abscess has been a challenge. Sir Williams MacEwen was called as the "father" of modern brain abscess management. Heineman and colleagues became the first to report the successful

medical management of a brain abscess in 1971. Medical therapy alone can be considered in patients with a lesion in the cerebritis stage since they are much more likely to respond to antibiotic therapy because of lack of a capsule and also for walled off, but < 2 to 3 cm in diameter abscess. The complexity of microbial flora in brain abscess necessitates empirical antibiotic therapy against both aerobic and anaerobic organisms. Usually, intravenous administration of “triple high dose” antibiotics (3rd generation cephalosporin + vancomycin and metronidazole) for 2 weeks followed by 4 weeks of oral therapy is recommended. Metronidazole is highly active against anaerobic bacteria, including *Bacteroides fragilis*, the most resistant anaerobe. Neurotoxicity such as seizures have been reported with imipenem and meropenem should be preferred for abscess due to multidrug-resistant *Enterobacter cloacae*. Antibiotic irrigation may prove helpful in case of rupture of a brain abscess (IVOBRA) into the ventricle.

If coagulation abnormalities are present, especially in cyanotic CHD, nonsteroidal anti-inflammatory drugs should be avoided, platelet concentrate should be available perioperatively and when the hematocrit > 65% requires phlebotomy and adequate hydration to maintain intravascular volume. Corticosteroids are used when a significant mass effect is visible on imaging and the patient’s mental status is depressed. Even though mannitol helps to decrease intracranial pressure, cerebral edema and ideal to reduce blood viscosity, it can cause severe dehydration, hypotension, tachycardia, acidosis and precipitate “tet spell” in cyanotic heart disease.

Surgery is the treatment of choice for most brain abscess. Needle aspiration is the most commonly used technique and total excision is preferred for solitary, superficial and well encapsulated abscesses. Neuroendoscopic technique with free hand stereotaxy has also been practiced and it has an additional advantage of more complete drainage and lavage, when compared to stereotactic aspiration. Antiepileptic medication was advised in all cases, then slowly withdrawn when the EEG become normal and the patient is seizure free for at least 2 years after surgery. Long term outcome in children with complete recovery is 30 %. The risk of recurrence is 10-50% and correction of cardiac anomaly is necessary to prevent recurrent brain abscess in cyanotic CHD.

References

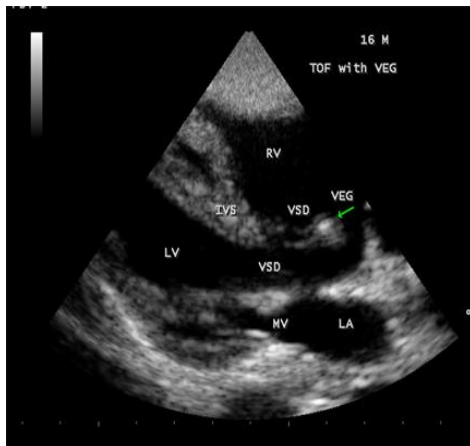
1. Muthiah, R. (2019) Infective Endocarditis in Tetralogy of Fallot Complicating Brain Abscess—A Case Report. *Case Reports in Clinical Medicine*, 8, 105-126.
2. Kagawa, M., Takeshita, M., Yato, S., et al. (1983) Brain Abscess in Congenital Cyanotic Heart Disease. *Journal of Neurosurgery*, 58, 913-917.
3. Rabinowitz, M.D., Weinstein, J. and Marcus, I.H. (1932) Brain Abscess (Paradoxical) in Congenital Heart Disease. *American Heart Journal*, 7, 790.
4. Prusty, G.K. (1993) Brain Abscesses in Cyanotic Heart Disease. *Indian Journal of Pediatrics*, 60, 43-53.

5. Lakhani, M.,Khan, F., Menon,S.. (2020) Brain abscess: A rare complication in a child with tetralogy of Fallot.IDCases,Volume 22, 2020, e00954

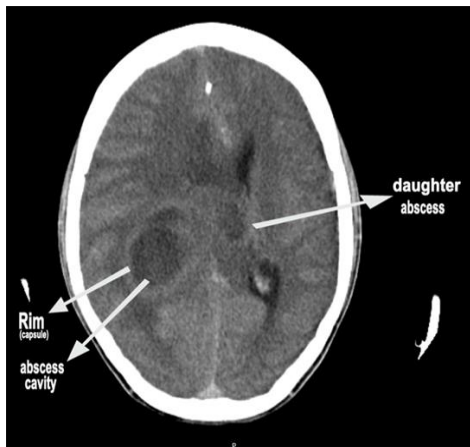
6.Ashraf, M., Ahmed, S., Hussain, M.(2017)

Burr hole aspiration of brain abscess in children with cyanotic heart disease

Journal of the College of Physicians and Surgeons, Pakistan, 27 , pp. 483-485



2D Echo Showing the “the vegetation” (arrow) attached to the crest of IVS (interventricular septum).



CT brain showing the large abscess cavity in the parietal lobe with small “daughter abscess” in the upper part (right arrow) in a 16-year old boy with Tetralogy of Fallot.